

Stentless Ureteroscopy for Uncomplicated Distal Ureteral Stones: A Prospective Study

(Prakash J.V.S¹, Jagatheswaran.C², Arasi K.V³, Natarajan.V⁴)

(Department of Urology, Govt Stanley Medical College, India)

(The Tamilnadu Dr.M.G.R Medical University)

Corresponding Author: Prakash J.V.S

Abstract: We compared outcome and complications after uncomplicated ureteroscopic treatment of distal ureteral calculi with or without the use of ureteral stents. 80 patients, prospectively divided into two groups to receive a double j stent (group 1, 42 patients), no stent (group 2, 38 patients), underwent ureteroscopic treatment of distal ureteral calculi. Stone characteristics, operative time, postoperative pain, lower urinary tract symptoms (LUTS), analgesia need, rehospitalization, stone-free rate, and late postoperative complications were all studied. There was no significant difference between the two groups regarding hematuria, fever, flank pain, urinary tract infection, and rehospitalisation. At 48 hours and 1 week, frequency/urgency and dysuria were significantly less in the nonstented group. When comparing group 1 and group 2, patients with double j stents had statistically significantly more bladder pain (P-0.003), frequency/urgency (P-0.002), dysuria (P-0.001), and need of analgesics (P-0.001). All patients who underwent imaging postoperatively were without evidence of obstruction or ureteral stricture.

Date of Submission: 16-04-2018

Date of acceptance: 04-05-2018

I Introduction

Placement of ureteral stents following ureteroscopic stone extraction has been common since the advent of ureteroscopy. Routine ureteral stenting following ureteroscopy has been suggested to decrease postoperative pain and stricture formation. Recent studies have demonstrated that stents do not need to be routinely inserted following uncomplicated ureteroscopic stone extraction. Borboroglu et al. demonstrated a comparable stone-free rate when comparing patients undergoing stented vs stentless ureteroscopy for the treatment of distal ureteral stones. Although proponents of stented ureterscopic stone extraction cite decreased postoperative pain to be associated with stent placement, recent studies have found postoperative pain, narcotic use, and urinary symptoms to be higher in stented groups of patients. Finally, a significant saving in cost is associated with stentless ureteroscopy

II Material And Methods

From January 2017 to July 2017, a total of 80 patients treated with successful ureteroscopy for distal ureteral stones were prospectively randomized to 2 groups. Group 1 included 42 patients in whom a double j stent was inserted, and group 2 included 38 patients in whom no stent was inserted after stone removal.

Study Design: Prospective open label observational study

Study Location: Department of urology, Govt Stanley medical College, India

Study Duration: January 2017 to July 2017

Sample size: 80 patients.

Sample size calculation: Total of 80 patients treated with successful ureteroscopy for distal ureteral stones were prospectively randomized to 2 groups. Group 1 included 42 patients in whom a double j stent was inserted, and group 2 included 38 patients in whom no stent was inserted after stone removal.

Inclusion criteria:

1. Either sex
2. Stone size less than 1 cm
3. Distal ureteric calculus

Exclusion criteria:

1. Stone size greater than 1 cm
2. B/L ureteric calculus
3. Stone in solitary functioning kidney

4. Impacted ureteric stone
5. Upper ureteric calculus

III Procedure Methodology

All procedures were performed under spinal anesthesia after discussion with patients. Informed consent was obtained from all patients. Patients were excluded from the study when stone size was greater than 1cm. The mean age was, respectively, 44.1 & 39.6 in group 1, group 2. Preoperative imaging consisted of KUB and renal ultrasonography with NCCT. Ureteroscopy was done with a 8-9.5 or 6-7.5 Fr semirigid ureteroscope. The pneumatic lithoclast was used to fragment the offending calculus into pieces in all cases requiring lithotripsy. The stents used in the study were 5Fr or 4 Fr in diameter. All patients in group 1 were rehospitalized after 2 weeks for double j stent removal. All patients were closely followed up

Procedures were considered a success if either a solitary calculus was removed in its entirety or all fragments were absent on radiographic followup. Radiographic followup typically consisted of a plain radiograph and renal ultrasound 1 month after the procedure. Age, gender, stone characteristics, total operating time, the mean operative time, and mean hospital stay were all recorded. For postoperative symptoms and the complications, a special questionnaire and a precise clinical exam were used, looking for flank pain, hematuria, dysuria, urgency, fever, and urinary tract infection. We also studied, the need of analgesics in postoperative time, the rate of rehospitalisation, and the appearance of an ureteral stricture. Patients were followed up postoperatively with a minimum of 3 months

IV Statistical Analysis

Differences in percentages (qualitative variables) were analyzed by the test. Kruskal-Wallis and Mann-Whitney test were used for comparison of treatment groups. Statistical analyses were performed using the SPSS 15.0. The value p of < 0.05 was considered statistically significant.

V Result

The 2 study groups were comparable regarding patients and stone characteristics (Table 1). Overall mean stone size in the study was 8.7 ± 1.3 mm. Moreover, the ureteroscopy technique, type of intracorporeal lithotripsy, and method of stone retrieval were not significantly different between the treatment groups

Table 1: Patient's characteristics and results

	Double j stent (group 1, 42 patients)	No stent (group 3, 38 patients) stent	P
Mean patient age (y, range)	44.1 (22-72)	43.2 (20-76)	0.24
Side of stone: R/L	16/26	20/18	0.12
Mean stone size (mm)	8.6 ± 1.4	8.2 ± 1.6	0.18
Mean operative time (min)	36 ± 4	31 ± 9	0.17
Success rate (%)	100	100	0.69

Ureteroscopy was successfully achieved in the two groups and the stone-free rate at 4 weeks was 100% in each group.

Mean operative time plus or minus standard deviation in group 1 was 36 ± 4 minutes, 34 ± 5 in group 2. Thus, operative time was not significantly longer when a double j stent was placed.

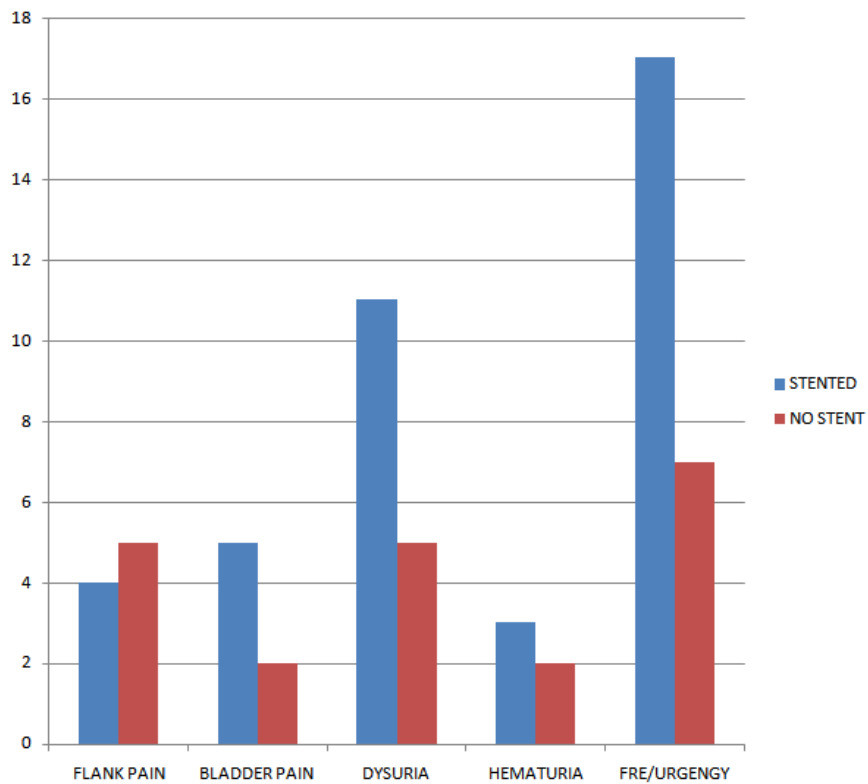
Table 2 shows the mean visual analog pain scores at 48 hours and 1 week after ureteroscopy and other postoperative symptoms and complications in the two groups.

Table 2: Postoperative symptoms and complications

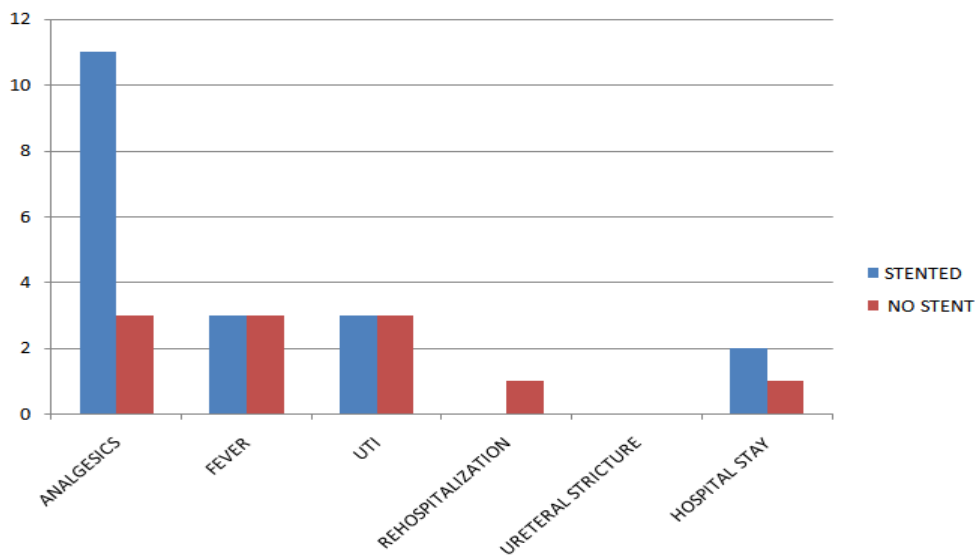
	Double j stent (group 1; 42 patients)	No stent (group 2; 38 patients) stent	P
Mean flank pain score at 48 hours (0-10) \pm S.D.	4.3 ± 2.1	4.7 ± 1.9	0.14
Mean flank pain score on day 7 (0-10) \pm S.D.	2.6 ± 1.4	2.1 ± 1.4	0.09
Mean bladder pain score at 48 hours (0-10) \pm S.D.	5.3 ± 2.6	2.2 ± 1.4	0.004
Mean bladder pain score on day 7 (0-10) \pm S.D.	4.8 ± 2.5	1.9 ± 1.1	0.003
Dysuria number (%)	11 (26.1)	5 (13.1)	0.002
Hematuria number (%)	3 (7.1)	2 (5.2)	0.67
Frequency/urgency number (%)	17 (40.4)	7 (18.4)	0.001
Need of analgesics in follow-up	11 (26.1)	3 (7.8)	0.001

Fever number (%)	3 (7.1)	3 (7.8)	0.5
Urinary tract infection number (%)	3 (7.1)	3 (7.8)	0.39
Rehospitalization number (%)	0	1	0.34
Ureteral stricture number (%)	0	0	0.70
Mean hospital stay (hours)	26	25	0.48

POST OPERATIVE SYMPTOMS



POST OPERATIVE SYMPTOMS



At 48 hours and 1 week, symptoms like frequency/urgency, dysuria were significantly less in the non stented group comparing to other groups. When comparing group 1 and group 2, patients with double j stents had statistically significantly more bladder pain (0.003), frequency/urgency (0.002), dysuria (0.001), and need of analgesics (0.001) compared to those without stents.

There was no significant difference between the two groups regarding hematuria, fever, flank pain, urinary tract infection, and rehospitalisation.

When taking into consideration all LUTS and the need of analgesics, they were significantly more important in the first group using a double pigtail stent group 1 versus group 2 (P- 0.001)

Readmission to the hospital for unremitting pain was necessary in 1 of 80 patients. No patients in the stented group required postoperative readmission to the hospital.

All complications were easily and successfully managed by conservative measures.

All patients (75%) who underwent imaging postoperatively were without evidence of obstruction or ureteral stricture on follow up imaging

VI Discussion

Ureteral stents are commonly placed after ureteroscopic stone extraction. The rationale for the routine use of ureteral stents after ureteroscopy originates from supposition, rather than from evidence-based medicine. However, the placement of a ureteral stent may be associated with significant morbidity.

Joshi et al. identified patient morbidity associated with ureteral stents as a significant health problem and investigated it in detail [5]. They found that ureteral stents are associated with significant symptoms, such as pain affecting daily activities (80%), urinary symptoms (73%), and reduced work capacity (58%), which reduce quality of life. During the research, it became clear that stents profoundly affect physical and psychosocial health and have a negative impact on functional capacity and work performance [3, 5].

In our present study involving 80 patients, we did not find significant difference between the two groups concerning flank pain, hematuria, fever, and urinary tract infection.

Several trials have demonstrated similar postoperative complication rates among stented and unstented patient populations. In the stented group, a cystoscopy is needed to remove the double J stent. The additional cystoscopy for stent removal is a cause of discomfort and overall cost.

VII Conclusion

The ureteral stent has become an integral part of the urological armamentarium. However, stent related morbidity is a reality in the majority of patients. Uncomplicated ureteroscopy for distal ureteral calculi without intraoperative ureteral dilation can safely be performed without placement of a ureteral stent. Patients without stents had significantly less pain, fewer urinary symptoms, and decreased analgesic use postoperatively and are not at risk of increased late complications. The other potential benefits to leaving patients without stents after ureteroscopy are cost savings and the avoidance of followup cystoscopy for stent removal

References

- [1]. G. M. Preminger, H. G. Tiselius, D. G. Assimos et al., "2007 guideline for the management of ureteral calculi," *European Urology*, vol. 52, no. 6, pp. 1610–1631, 2007. View at Publisher · View at Google Scholar
- [2]. D. H. Hosking, S. E. McColm, and W. E. Smith, "Is stenting following ureteroscopy for removal of distal ureteral calculi necessary?" *Journal of Urology*, vol. 161, no. 1, pp. 48–50, 1999. View at Publisher · View at Google Scholar · View at Scopus
- [3]. H. B. Joshi, N. News, A. Stainthorpe, R. P. MacDonagh, F. X. Keeley Jr., and A. G. Timoney, "Ureteral stent symptom questionnaire: development and validation of a multidimensional quality of life measure," *Journal of Urology*, vol. 169, no. 3, pp. 1060–1064, 2003. View at Publisher · View at Google Scholar · View at Scopus
- [4]. M. Duvdevani, B. H. Chew, and J. D. Denstedt, "Minimizing symptoms in patients with ureteric stents," *Current Opinion in Urology*, vol. 16, no. 2, pp. 77–82, 2006. View at Publisher · View at Google Scholar · View at Scopus
- [5]. H. B. Joshi, A. Stainthorpe, R. P. MacDonagh, F. X. Keeley Jr., and A. G. Timoney, "Indwelling ureteral stents: evaluation of symptoms, quality of life and utility," *Journal of Urology*, vol. 169, no. 3, pp. 1065–1069, 2003. View at Publisher · View at Google Scholar · View at Scopus

Prakash J.V.S." Stentless Ureteroscopy For Uncomplicated Distal Ureteral Stones: A Prospective Study." *IOSR Journal of Dental and Medical Sciences (IOSR-JDMS)*, vol. 17, no. 5, 2018, pp 10-13.